

## **REPAIRS AND ADDITIONS TO REMOVABLE PARTIAL DENTURES**

The need for repairing or adding to a removable partial denture will occasionally arise. However the frequency of this occurrence should be held to a minimum by careful diagnosis, intelligent treatment planning, adequate mouth preparations, and the carrying out of an effective removable partial denture design with proper fabrication of all component parts. Any need for repairs or additions will then be the result of unforeseen complications that arise in abutment or other teeth in the arch, breakage or distortion of the denture through accident, or careless handling by the patient rather than to faulty design or fabrication.

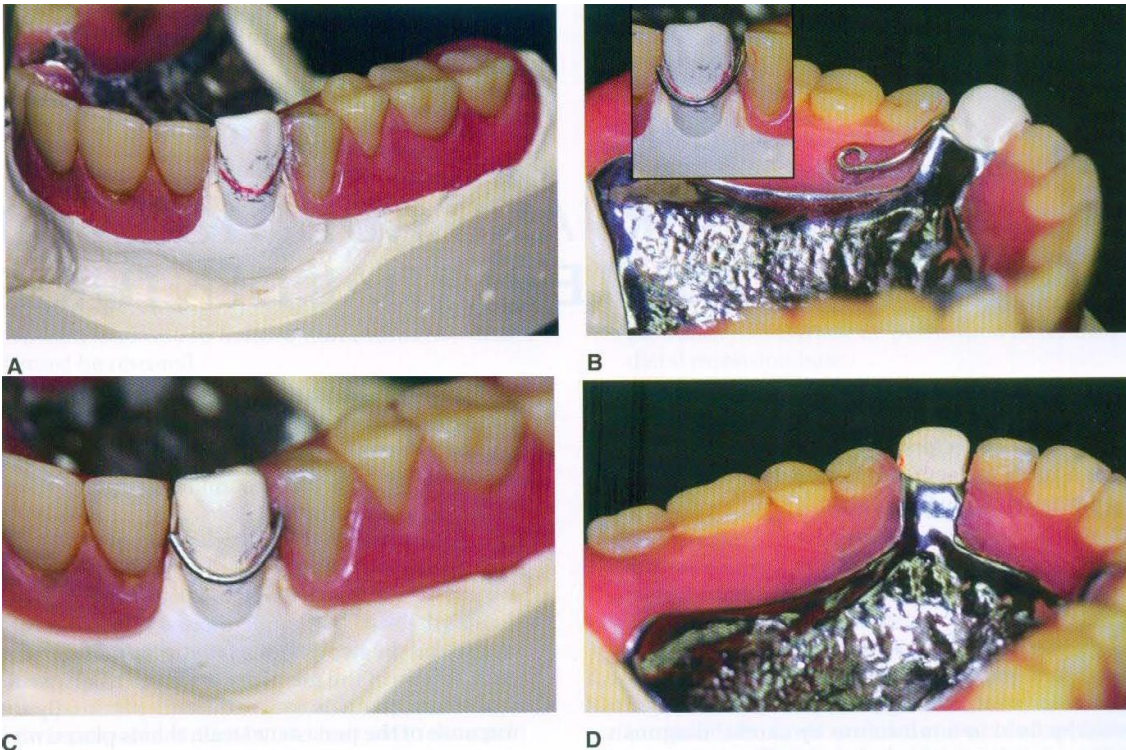
It is important that the patient should be instructed in the proper placement and removal of the prosthesis so that undue strain is not placed on clasp arms, on other parts of the denture, or on contacted abutment teeth. The patient also should be advised that care must be given to the prosthesis when it is out of the mouth and that any distortion may be irreparable. It should be made clear that there can be no guarantee against breakage or distortion from causes other than obvious structural defects.

### **A- BROKEN CLASP ARMS:**

The following are several reasons for breaking of clasp arms:

1- Breakage may result from repeated flexure into and out of too severe an undercut. If the periodontal support is greater than the fatigue limit of the clasp arm, failure of the metal occurs first. Otherwise the abutment tooth is loosened and eventually lost because of the persistent strain that is placed on it. Locating clasp arms only where an acceptable minimum of retention exists, as determined by an accurate survey of the master cast, can prevent this type of breakage.

2- Breakage may occur as a result of structural failure of the clasp arm itself. A cast clasp arm that is not properly formed or is subject to careless finishing and polishing will eventually break at its weakest point. This can be prevented by providing the appropriate taper to flexible retentive clasp arms and uniform bulk to all rigid nonretentive clasp arms. Wrought-wire clasp arms may eventually fail because of repeated flexure at the region where it exits from the resin base, see (Figure-1- ).



**(Figure-1- )** {Fractured direct retainer on canine abutment. Reason for breakage is likely the long- term repeated flexure from movement associated with this 8 years old distal extension prosthesis. Denture must be evaluated for prospective serviceability if retainer arm is repaired. Often, patient will best be served by replacing denture with new restoration. **A:** cast produced from irreversible hydrocolloid impression, height of contour is shown in pencil with red line illustrating to lab the location of repair wire (18 gauge).**B:** Clasp adapted to designated line on canine and fitted into resin trough distal to canine and palatal to first and second premolars. Note the curvature placed at the end of the wire to prevent movement within polymerized resin. **C:** Finished and polished wire repair from the buccal and **D:** Palatal view}.

or at a point at which a nick or constriction occurred as a result of careless use of contouring pliers. They also may break at the point of origin from the casting as a result of excessive manipulation during initial adaptation to the tooth or subsequent readaptation. Clasp braking can best be prevented by cautioning the patient against removing the removable partial denture by sliding the clasp arm away from the tooth with the fingernails. A wrought-wire clasp arm can normally be adjusted several times over a period of years without failure. It is only when the number of adjustment is excessive that breakage is likely to occur. Wrought-wire clasp arms also may break at the point of origin because of recrystallization of the metal. This can be prevented by proper selection of wrought wire, avoiding burnout temperatures exceeding 1300°F. When wrought wire is attached to the framework by soldering, the soldering technique must avoid recrystallization of the wire. For this reason, it is best that soldering be done electrically to prevent the wrought wire from overheating. A low-fusing (1420° to 1500° F), triple-thick color-matching gold solder should be used rather than a solder that possesses a higher fusing temperature.

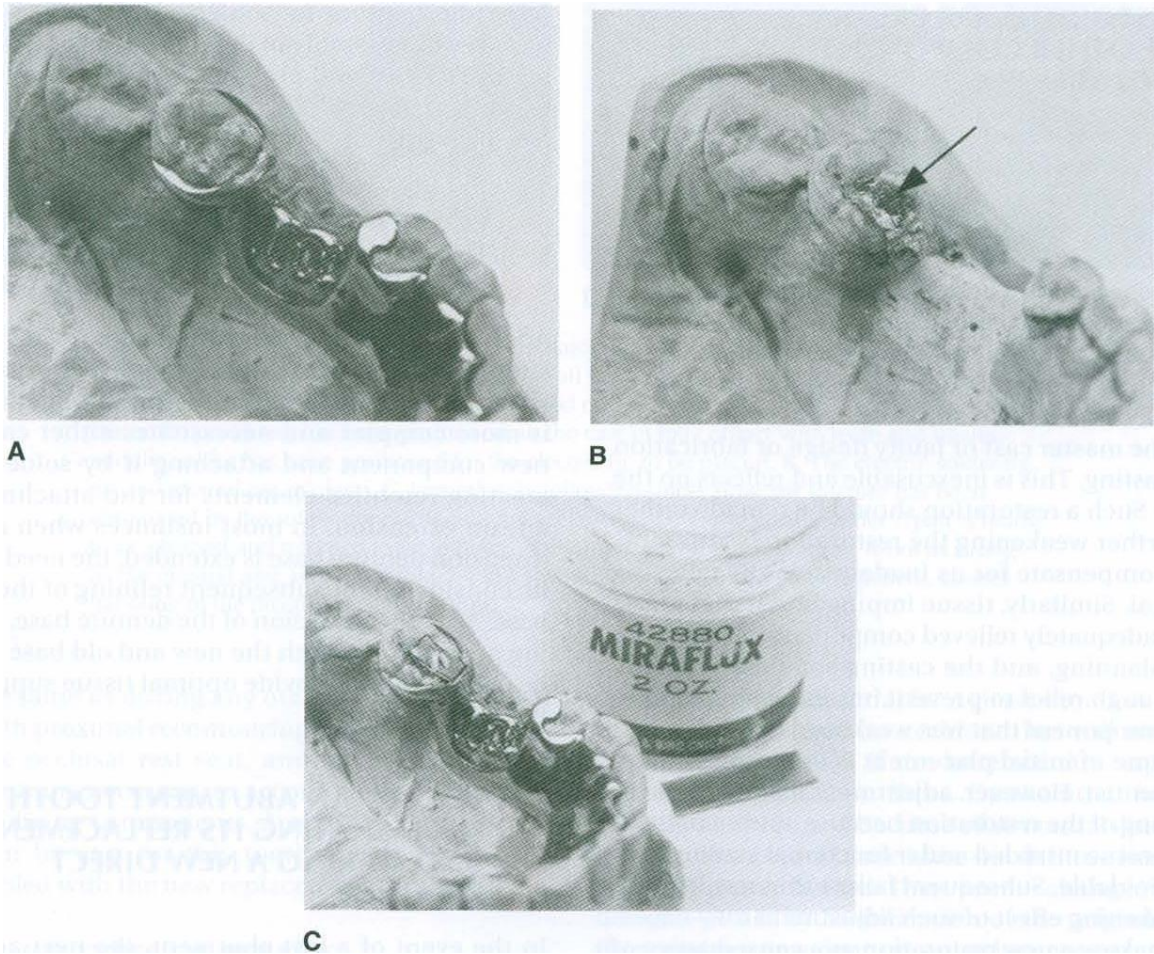
3- Breakage may occur because of careless handling by the patient. Any clasp arm will become distorted or will brake if subjected to excessive abuse by the patient. The most common cause of failure of a cast clasp arm is distortion caused by accidentally dropping the removable partial denture. A broken retentive clasp arm, regardless of its type, may be replaced with a wrought-iron retentive arm embedded in a resin base, see (Figure-1- ) or attached to a metal base by electric soldering. Often this avoids the necessity of fabricating an entirely new clasp arm.

**B- FRACTURED OCCLUSAL RESTS:**

Breakage of an occlusal rest almost always occurs where it crosses the marginal ridge. Improperly prepared occlusal rest seats are the usual cause of such weakness; an occlusal rest that crosses a marginal ridge that was not lowered sufficiently during mouth preparations either is made too thin or is thinned by adjustment in the mouth to prevent occlusal interference. Failure of an occlusal rest rarely results from a structural defect in the metal and rarely if ever is caused by accidental distortion. Therefore the blame for such failure must often be assumed by the dentist for not having provided sufficient space for the rest during mouth preparations.

Soldering may repair broken occlusal rests. In preparation for the repair, it may be necessary to alter the rest seat of the broken rest or to relieve occlusal interferences. With the removable partial denture in its terminal position, an impression is made in irreversible hydrocolloid and then removed, with the removable partial denture remaining in the impression. The dental stone is poured into the impression and allowed to set. The removable partial denture is then removed from the cast, and platinum foil is

adapted to the rest seat and the marginal ridge and overlaps the guiding plane. The removable partial denture is returned to the cast and, with a fluoride flux, gold solder is electrically fused to the platinum foil and minor connector in sufficient bulk to form an occlusal rest, see (Figure-2- ).



**(Figure-2- )** { **A:** Occlusal rest on molar fractured and was lost. Adequacy of present rest seat must be evaluated as well as interocclusal space available for rest before repair procedure is undertaken. **B:** Denture is removed from cast, and platinum foil (arrow) is adapted to rest seat area and over marginal ridge of abutment. **C:** Flux is applied sparingly to areas involved and solder is placed in position }.

An alternative solder to use is an industrial brazing alloy, which is higher fusing but responds excellently to electric soldering and does not tarnish, see (Figure-3- ).



**A**

**B**

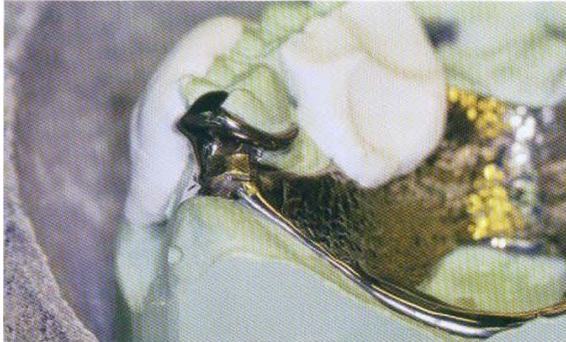(**Figure-3-** ) {**A:** Electrical soldering is used to repair rest. **B:** Rest is shaped to conform to rest seat outline. Framework is tried in patient's mouth for any necessary adjustment and rest is polished}.

### **C- DISTORTION OR BREAKAGE OF MAJOR AND MINOR CONNECTORS:**

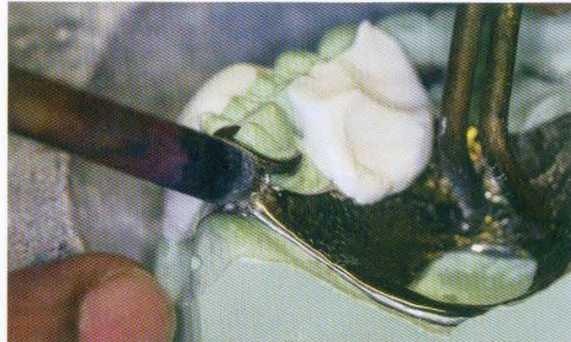
Assuming that major and minor connectors were originally made with adequate bulk, distortion usually occurs from abuse by the patient. All such components should be designed and fabricated with sufficient bulk to ensure their rigidity and permanence of form under normal circumstances.

Major and minor connectors occasionally become weakened by adjustment to prevent or eliminate tissue impingement. Such adjustment at the time of initial placement is a result of either inadequate survey of the master cast or faulty design or fabrication of the casting. This is inexcusable and reflects on the dentist. Such a restoration should be remade rather than further

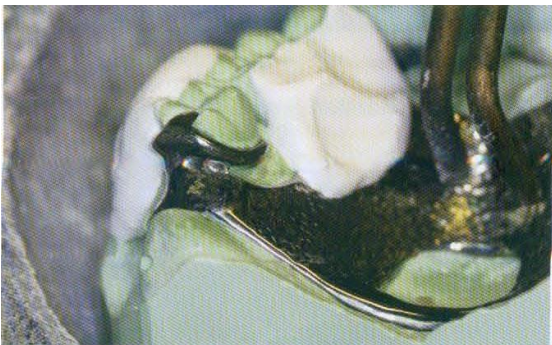weakening the restoration by attempting to compensate for its inadequacies by relieving the metal. Similarly, tissue impingement that arises from inadequately relieved components results from faulty planning, and the casting should be remade with enough relief to prevent impingement. Failure of any component that was weakened by adjustment at the time of initial placement is the responsibility of the dentist. Commonly, repeated adjustment to a major or minor connector results in a loss of rigidity to the point that the connector can no longer function effectively. In such situations, either a new restoration must be made or that part must be replaced by casting a new section and then reassembling the denture by soldering. The cost and probable success must then be weighed against the cost of a new restoration. Generally the new restoration is advisable, see (Figure-4- ).



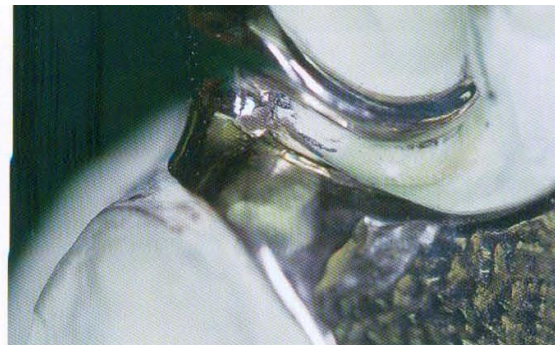A



B



C

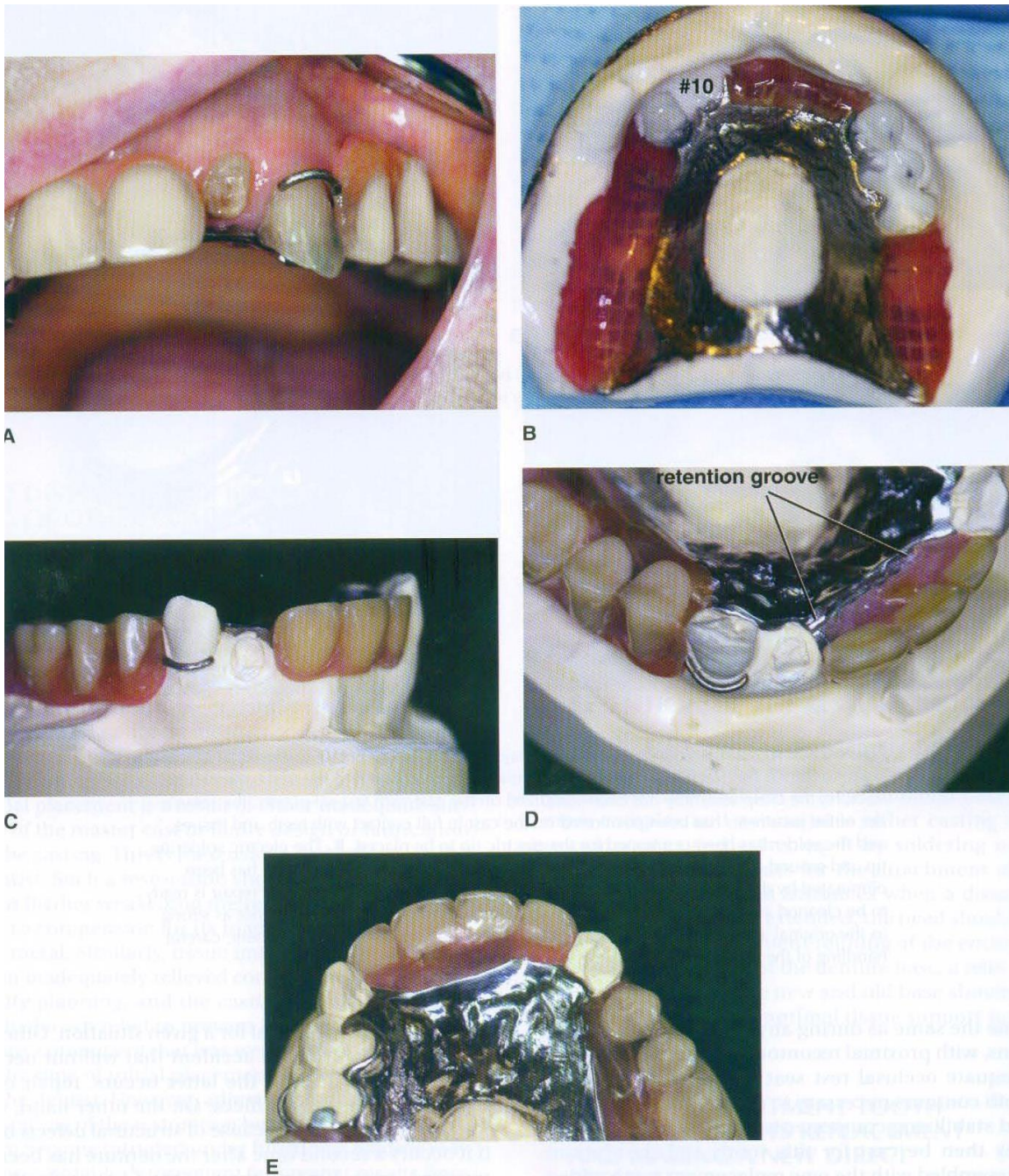


D

**(Figure-4- )**{ **A:** Maxillary juncture between major and minor connector at the distal of most posterior molar has fractured. Thin platinum foil has been adapted to the cast beneath the fracture, the clasp assembly has been stabilized on the cast with fast-set plaster, the remainder of the prosthesis has been positioned on the cast in full contact with teeth and tissues, and the solder has been positioned for the electric tip to be replaced. **B:** The electric soldering tip and ground are in place **C:** Immediately following solder flow, the fracture has been eliminated by the solder connecting the tow segments **D:** The polished solder repair is ready to be cleaned and returned to the patient. The patient is told that the repair is not as strong as the original and while it is difficult to know how long it could serve the patient, careful handling of the prosthesis is mandatory }.

**D- LOSS OF A TOOTH OR TEETH NOT INVOLVED IN THE SUPPORT OR RETENTION OF THE RESTORATION:**

Additions to a removable partial denture are usually simply made when the bases are made of resin, see (Figure-5- ). The addition of teeth to metal bases is more complex and necessitates either casting a new component and attaching it by soldering or creating retentive elements for the attachment of a resin extension. In most instances when distal extension denture base is extended, the need should be considered for subsequent relining of the entire base. After the extension of the denture base, a relining procedure of both the new and old base should be carried out to provide optimal tissue support for the restoration.



**(Figure-5- )**{This patient presented with an asymptomatic fractured lateral incisor. **A:** Clinical presentation of fractured tooth and prosthesis. Evaluation of the prosthesis revealed it to be adequately fitting, stable and retentive. **B:** Pick-up impression of prosthesis. **C:** Cast formed from pick-up impression showing a fully seated prosthesis. **D:** Preparation of the prosthesis included mechanical means for retention (which was provided by creating a recess in the resin adjacent to the missing tooth), and creating a trough at the external finishing line to

repair an area of marginal breakdown. **E:** Finished repair that will be taken to the mouth and checked for occlusal clearance lingual to the maxillary anterior teeth }.

**D- LOSS OF AN ABUTMENT TOOTH NECESSITATING ITS REPLACEMENT AND MAKING A NEW DIRECT RETAINER**

In the event of a lost abutment, the next adjacent tooth is usually selected as a retaining abutment and it generally will require modification or a restoration. Any new restoration should be made to conform to the original path of placement, with proximal guiding plane, rest seat, and suitable retentive area. Other wise modifications to the existing tooth should be done the same as during any other mouth preparations, with proximal recontouring, preparation of an adequate occlusal rest seat, and any reduction in tooth contours necessary to accommodate retentive and stabilizing components. A new clasp assembly may then be cast for this tooth and the denture reassembled with the new replacement tooth added.